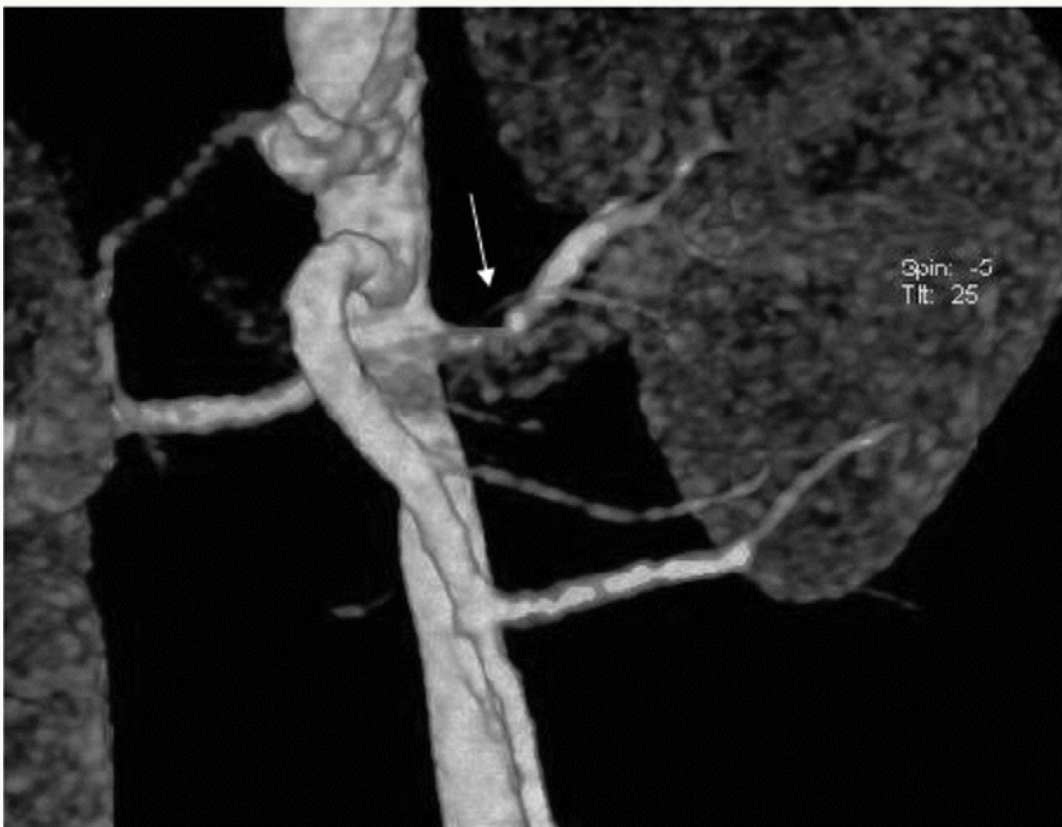




Renal Artery Stenosis



Significant renal artery stenosis (arrow) in a patient with severe hypertension.

Theos A et al. *Ann Intern Med* 2006;144:844.