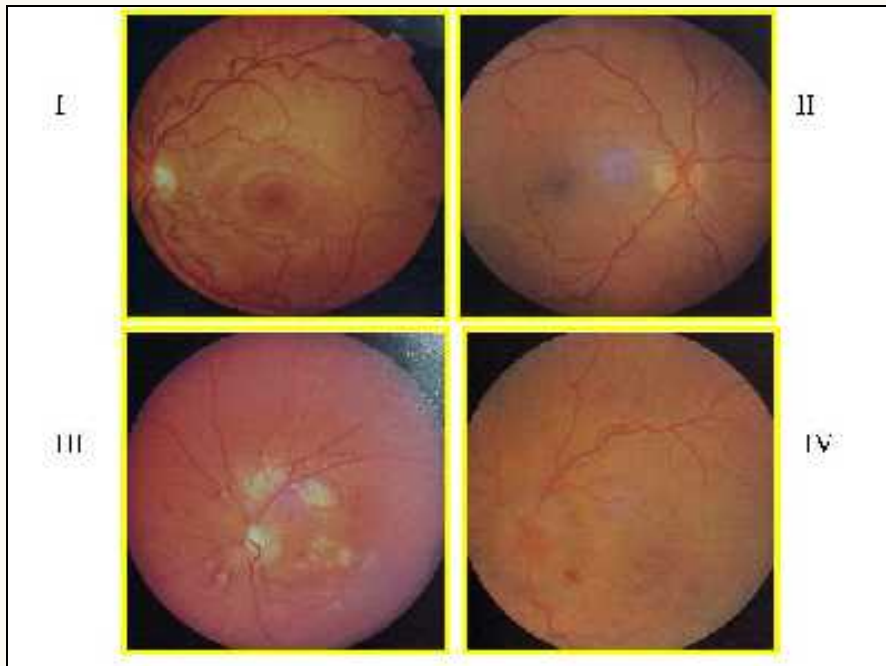




Eye Grounds



Hypertension eye grounds, grades 1-4. Grade 1: Narrowing in terminal branches of vessels. Grade 2: General narrowing of vessels with severe local constriction. Grade 3: To the preceding signs are added striate hemorrhages and soft exudates. Grade 4: To the preceding signs is added papilledema.