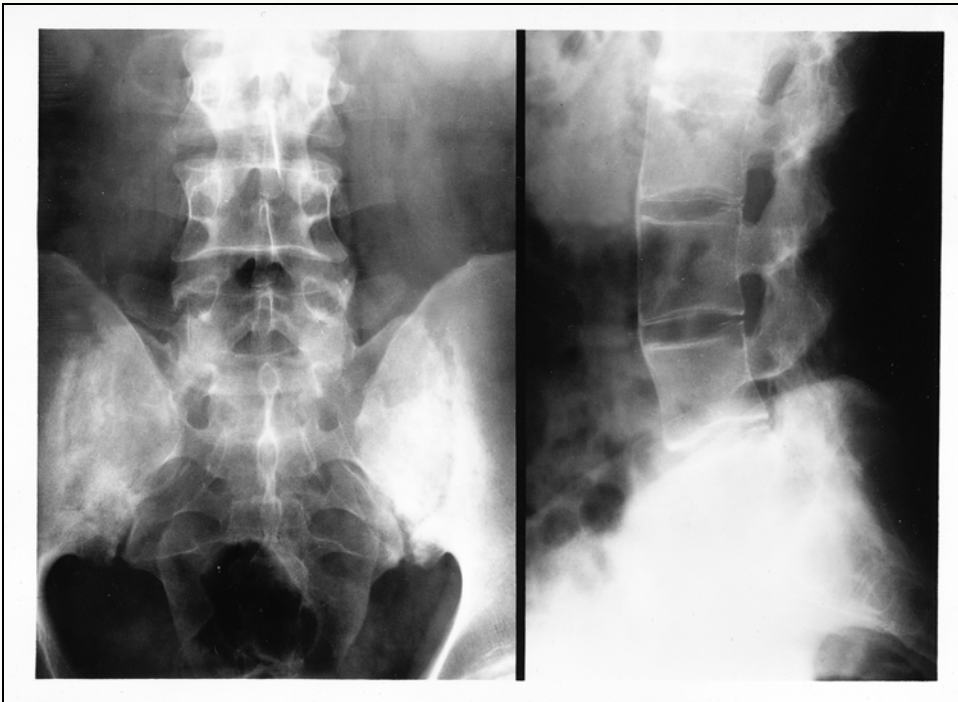




Ankylosing Spondylitis



Lumbar Spine and Pelvic X-rays Showing Ankylosing Spondylitis: The anteroposterior view shows sclerosis and erosions of both sacroiliac joints and the lateral view shows bridging of the intervertebral disc space by syndesmophytes characteristic of ankylosing spondylitis.