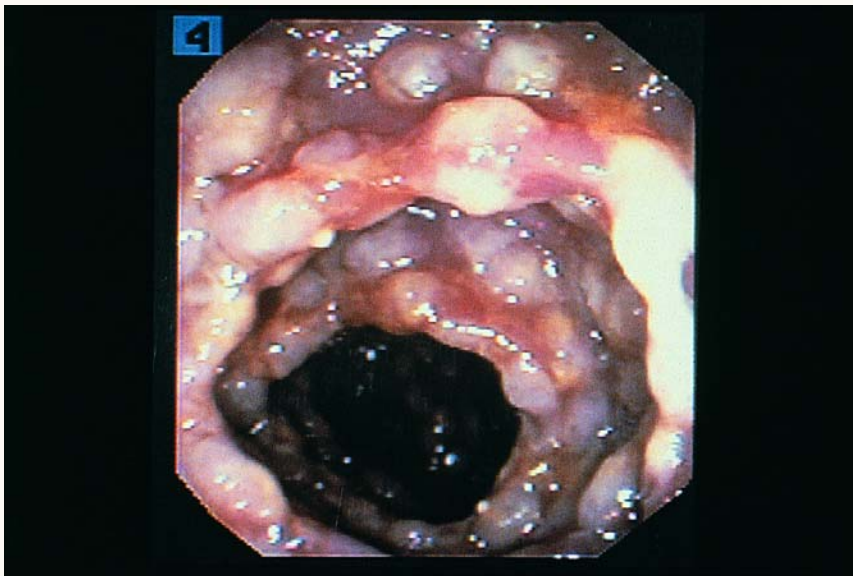




Clostridium difficile Colitis



White to yellow pseudomembranes on top of the mucosa, being separated by areas of relatively normal mucosa. Normal colonic mucosa is shiny with fine, visible vessels.