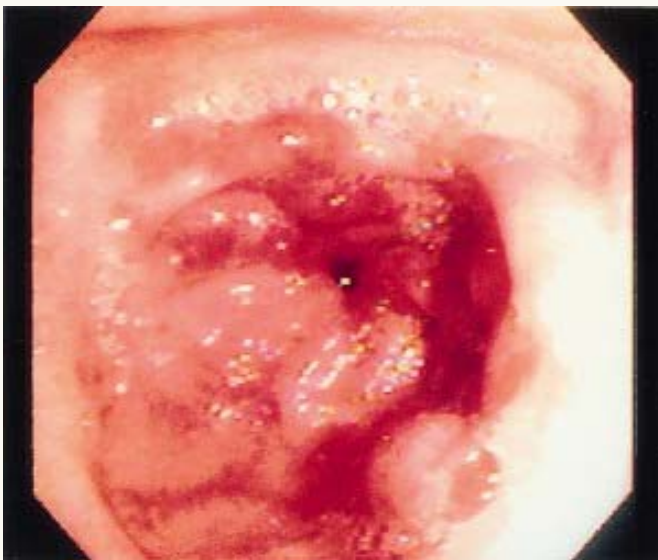




Gastric Antral Vascular Ectasias (GAVE)



The endoscopic view of gastric antral vascular ectasias (GAVE). The pattern of the vascular dilatation resembles "watermelon" stripes and can be a source of gastrointestinal blood loss.