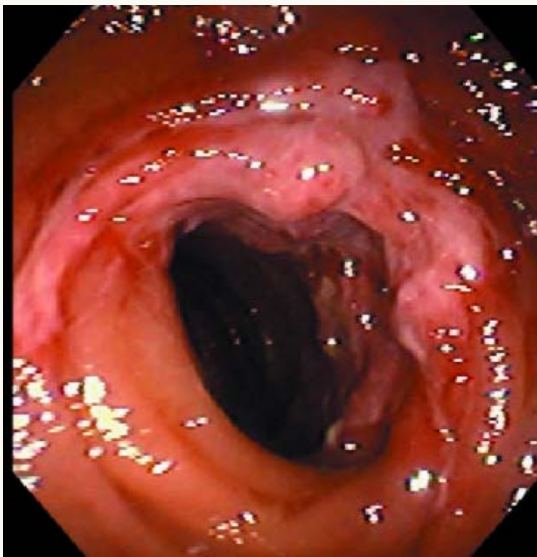




Ischemic Colitis



Colonoscopic view of ischemic colitis revealing necrosis and mucosal friability; ulcers with surrounding edema may sometimes be seen. The normal colonic mucosa has easily visible fine vessels and the surface is smooth and shiny.