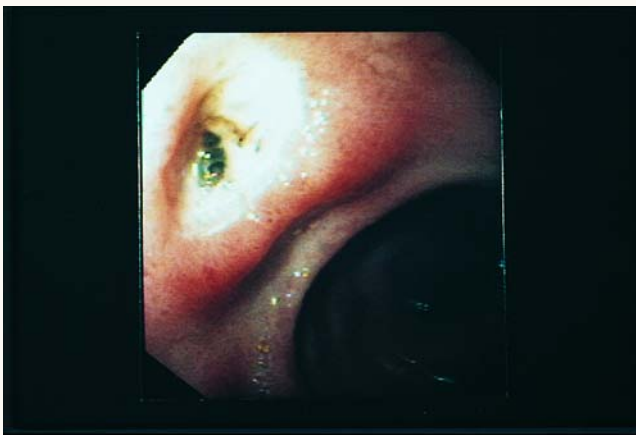




Visible Vessel



A green appearing visible vessel at the base of a peptic ulcer. Independent endoscopic predictors of rebleeding in patients include arterial spurting (55% to 90% recurrence rate), a visible vessel (40% to 50%), and adherent clot that does not wash off (10% to 35%).