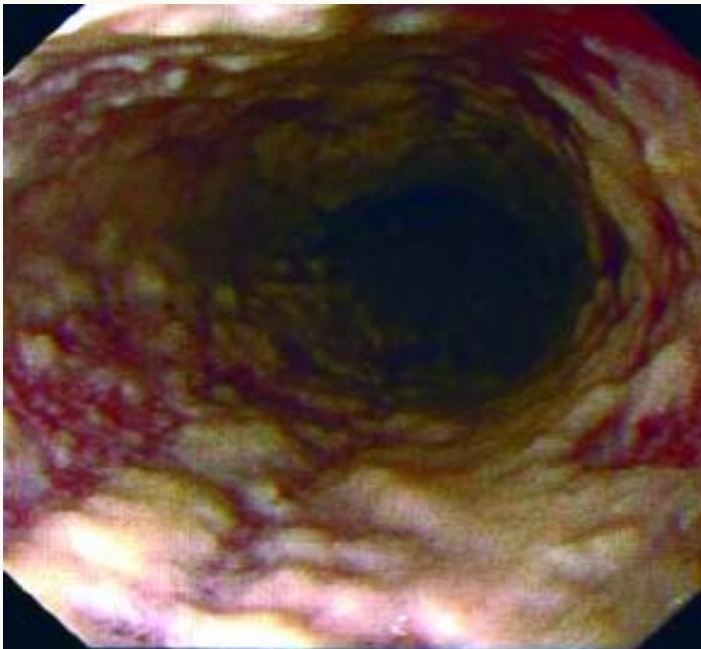




Candida Esophagitis



Note the patchy white, curd-like plaques on the esophagus characteristic of Candida esophagitis. This patient had HIV disease and a low CD4 count.