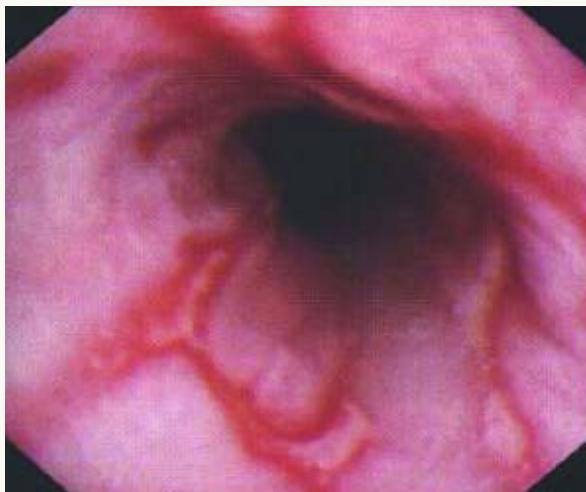




Erosive Esophagitis



Note the beefy red erosions characteristic of erosive esophagitis secondary to gastroesophageal reflux disease.