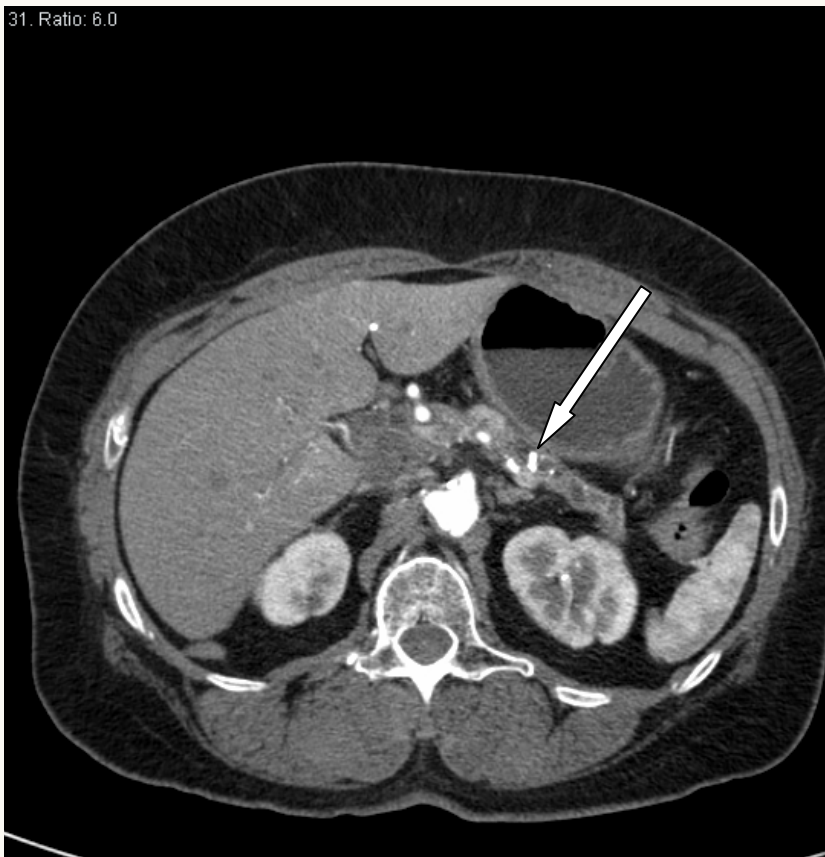




## Pancreatic Calcifications



CT scan of abdomen: CT scan showing calcifications in a patient with acute and chronic pancreatitis.

From *MKSAP 14, Gastroenterology and Hepatology*.