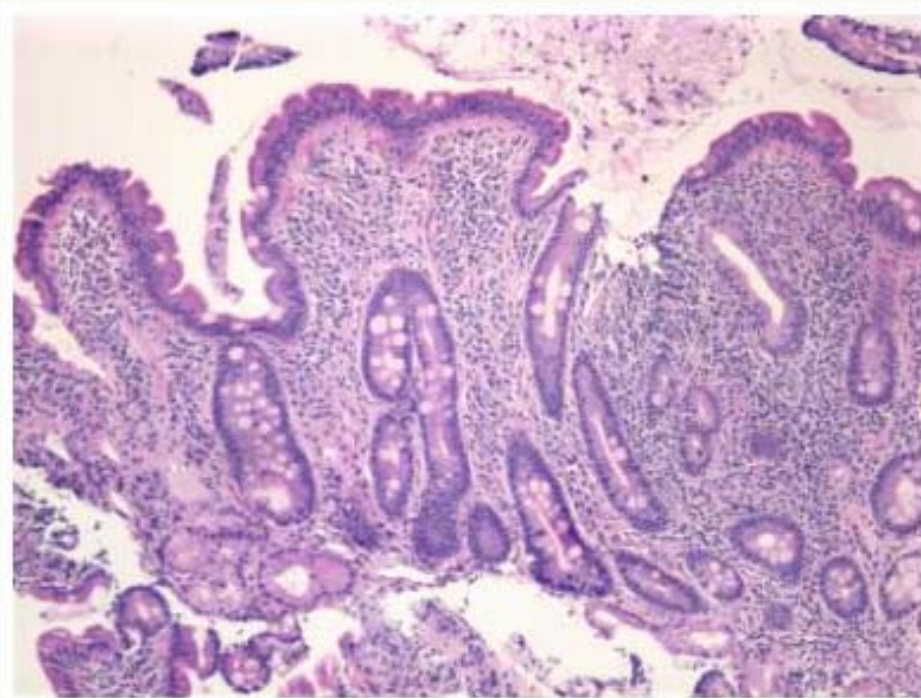




Celiac Disease



In this patient with celiac disease, there is loss of the villous architecture and crypt hyperplasia and increased inflammatory infiltration of the lamina propria.