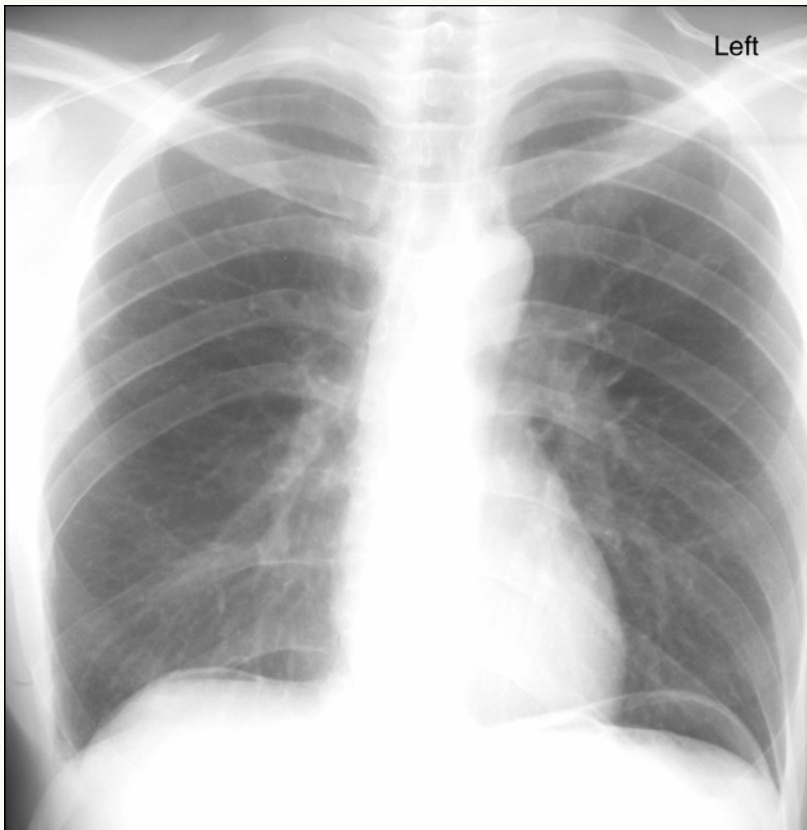




Pneumoperitoneum



Plain abdominal x-ray showing free air beneath the diaphragms suggesting the presence of a perforated air-containing organ such as the stomach or duodenum.