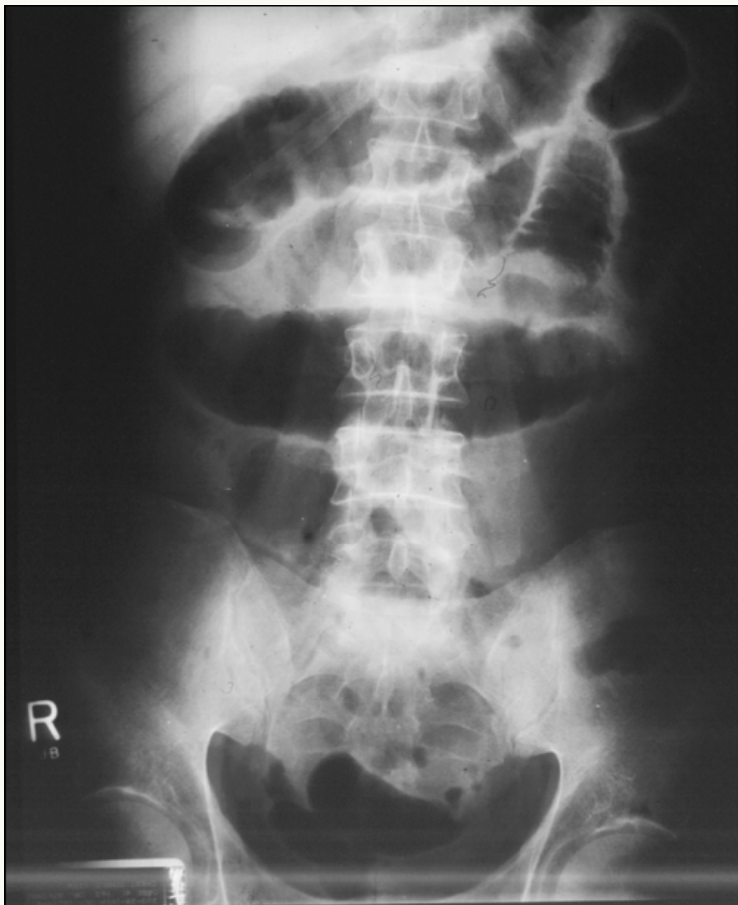




Small Bowel Obstruction



Abdominal x-ray showing small bowel obstruction with horizontally oriented, dilated loops of small bowel resembling steps of a ladder.