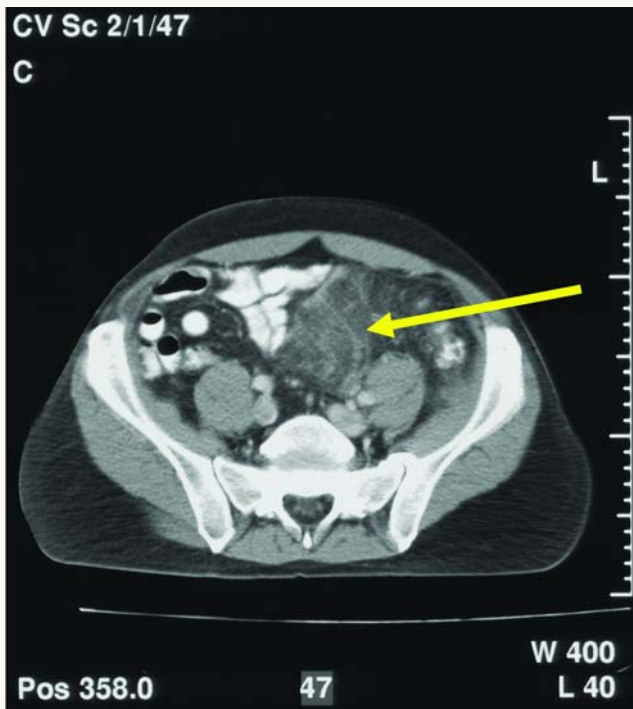




Diverticular Abscess



CT scan showing sigmoid inflammatory changes associated with acute diverticulitis and a diverticular abscess (arrow).