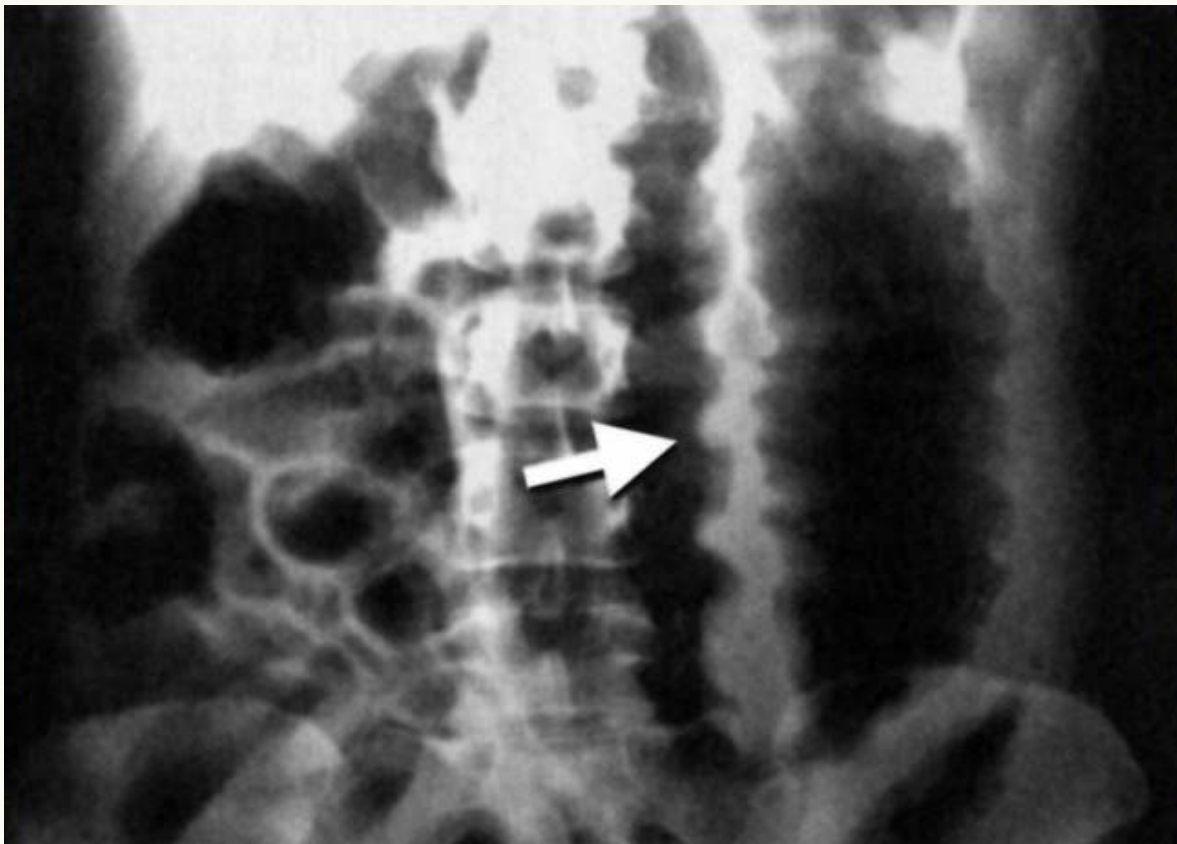




Toxic Megacolon



Plain abdominal x-ray showing a grossly dilated descending colon and edematous bowel wall (arrow) that is associated antibiotic associated *Clostridium difficile* colitis.