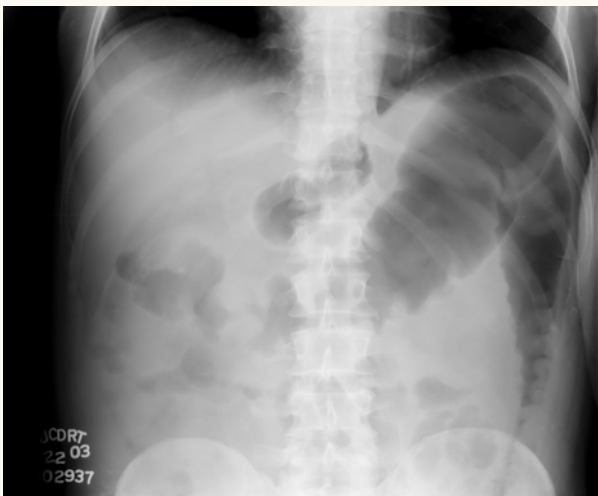




Thumprinting



The plain abdominal x-ray shows thumbprinting, an indication of mucosal edema, associated with ischemic colitis. Found in approximately 30% of patients with mesenteric ischemia, it is associated with a poor prognosis.