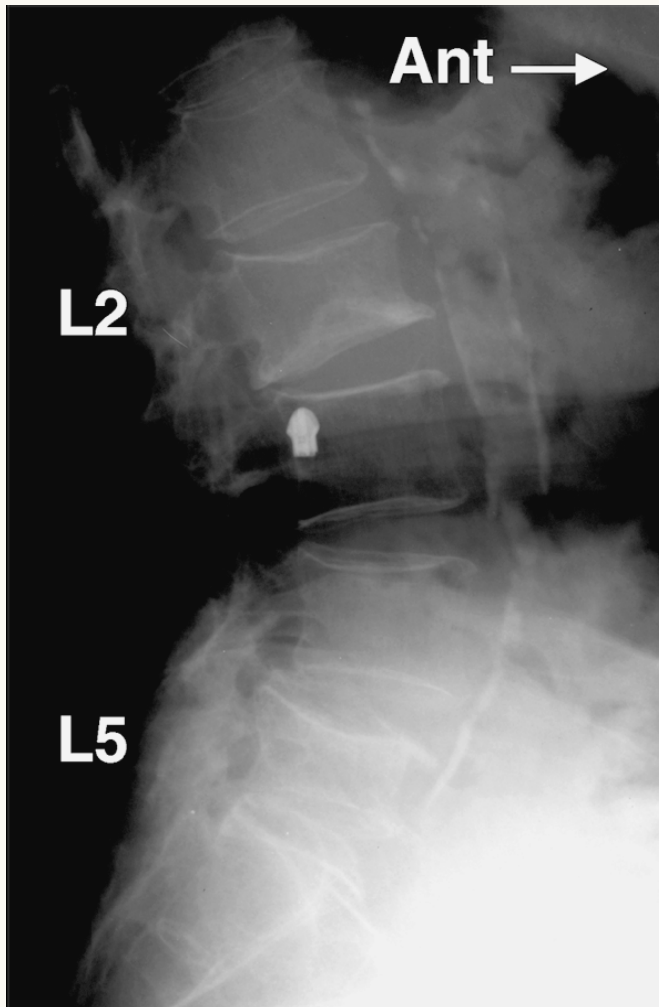




## Compression Fracture



Lumbar spine x-ray showing L2 vertebral wedge compression fracture and osteopenia, probably secondary to osteoporosis. Many osteoporotic compression fractures are discovered incidentally on chest radiographs.