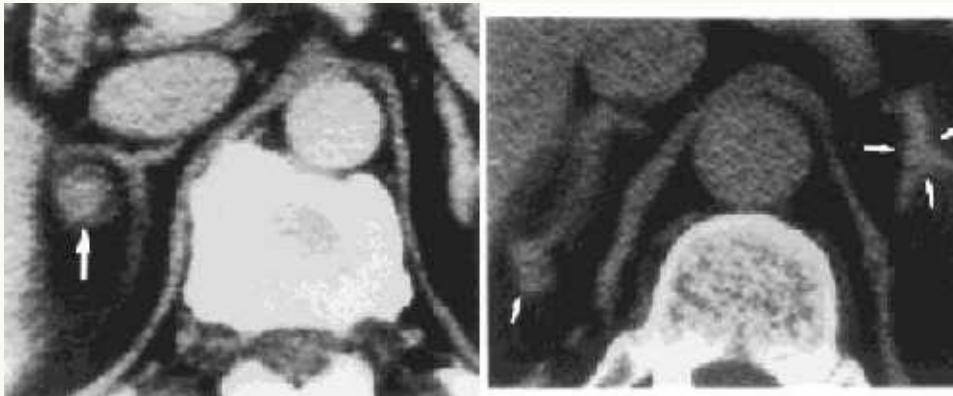




Adrenal Adenoma



A 1.5 cm right adrenal cortical adenoma (arrow) on contrast enhanced CT scan.