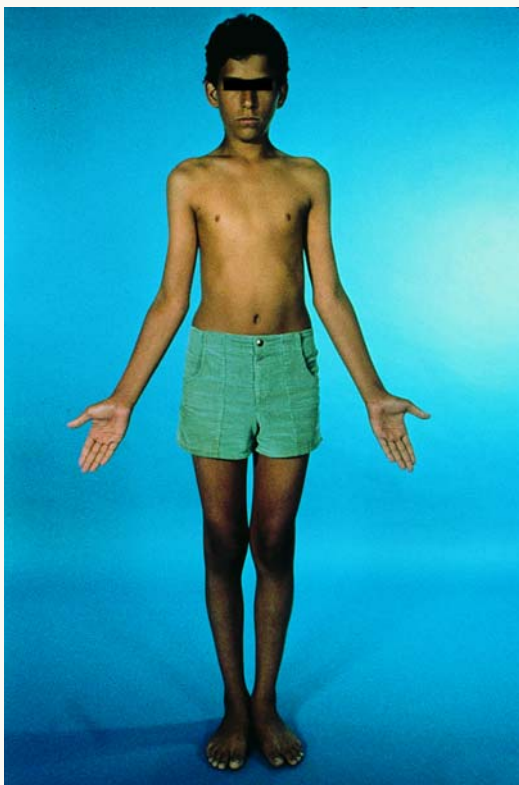




## Addison's Disease



Note the darkly pigmented patient that is seen in some patients with long-standing Addison's disease. Early cutaneous signs may include darkly pigmented scars or palmar creases, which are faintly visible in this image.