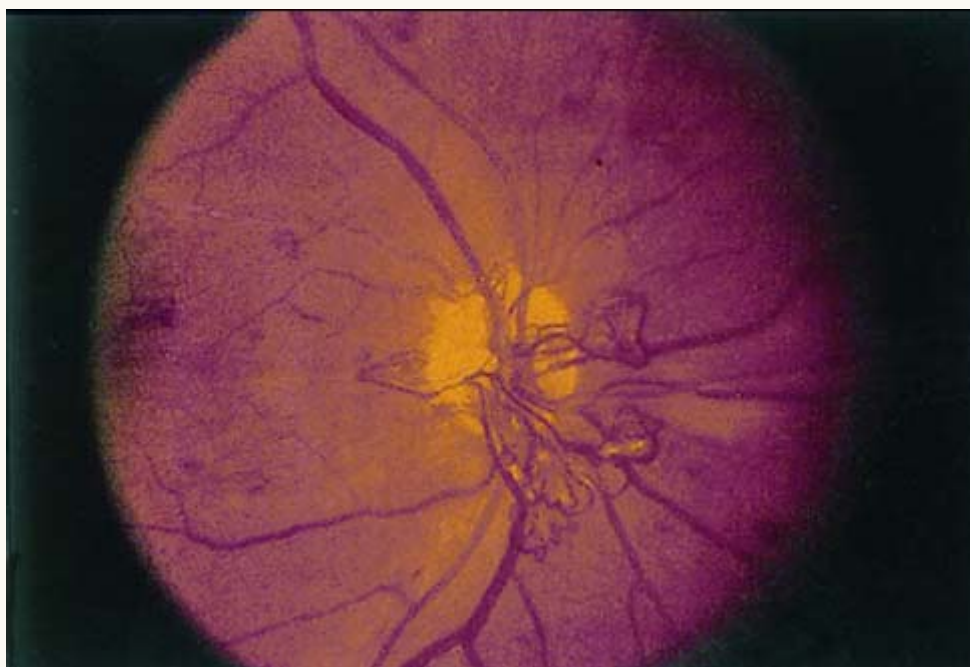




Diabetic Retinopathy



This retina is an example of proliferative diabetic retinopathy and is characterized by the ischemia-induced development of a network of new vessels protruding from the optic disk (left panel). These vessels can rupture and lead to preretinal or vitreous hemorrhage. The right panel shows the nonproliferative retinopathy. The red dots represent microaneurysms or microhemorrhages. Flame hemorrhages (intraretinal hemorrhages) and hard exudates (yellow) are also present.