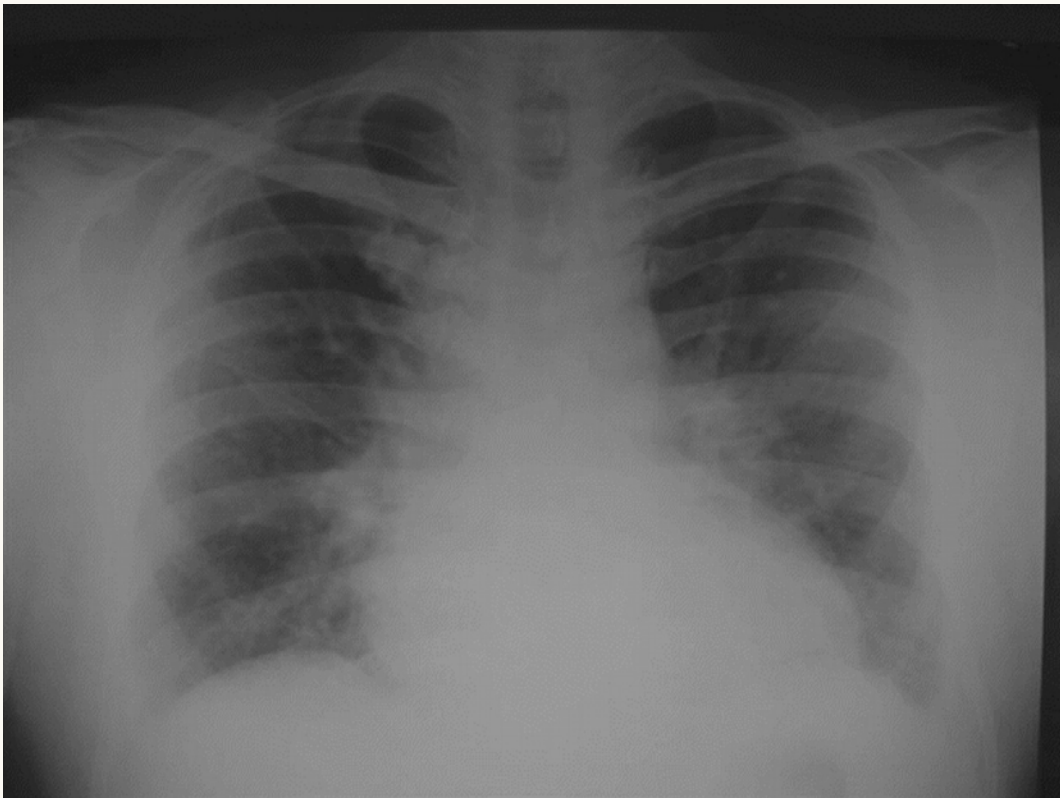




Heart Failure Radiograph



Chest x-ray showing cardiomegaly, perihilar infiltrates, and pulmonary vascular congestive characteristic of severe heart failure with pulmonary edema.