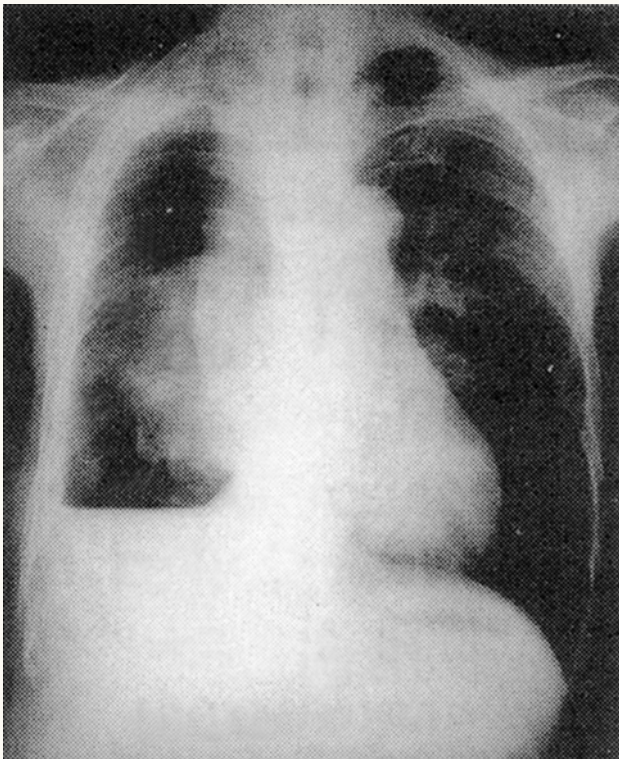




Pneumothorax



The x-ray shows a large pneumothorax on the right side of the chest and accumulation of fluid at the right base, resulting in a hydropneumothorax. The radiographic findings characteristic of a pneumothorax include loss of normal lung markings at the periphery of the hemithorax and the presence of a well defined visceral pleural line at some point between the chest wall and the hilum.