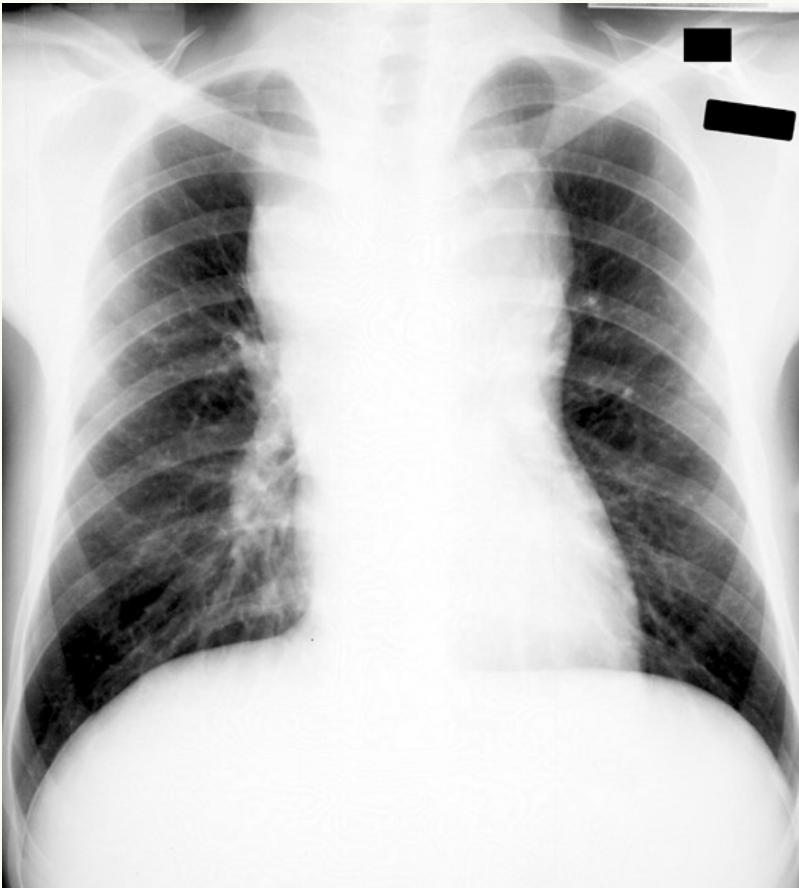




## Mediastinal Widening



This x-ray shows mediastinal widening in the upper portion of the mediastinum. Various conditions can cause this appearance including lymphadenopathy, thymoma, and thoracic aortic aneurysm. In a patient with acute chest pain and evidence of hemodynamic instability, think first of aortic dissection and follow up with either a bedside echocardiogram, CT scan of the chest, or MRI.